

# The Accuracy of the Retcam as a Wide-Field Digital Retinal Imaging Device Relative to Binocular Indirect Ophthalmoscopy for the Diagnosis of Retinopathy of Prematurity: A Systematic Review of Diagnostic Test Accuracy

Shannon Brown BAppSc MOrth

Discipline of Orthoptics, School of Allied Health, Human Services and Sport, La Trobe University, Melbourne, Australia

## ABSTRACT

**Objective:** To assess the diagnostic test accuracy of the RetCam, a wide-field digital retinal imaging device, for the detection of referral-warranted or treatment-requiring retinopathy of prematurity (ROP), using binocular indirect ophthalmoscopy (BIO) as the reference standard for screening in premature infants. ROP is a sight-threatening condition of the immature retina requiring diagnosis by a trained ophthalmologist. An alternative method for performing a comprehensive retinal examination of a neonate for the diagnosis and staging of ROP is necessary to meet the increasing demand for screening, improve access and reduce costs.

**Method:** Database searches of CINAHL, PubMed, Embase, SCOPUS and CENTRAL were conducted on the 20th May 2021 for articles published from 2010 onwards. Studies where infants were tested with both the RetCam and BIO were included. The QUADAS-2 quality assessment checklist was utilised to assess any bias or applicability concerns for each study. Study data was synthesised in narrative and tabular form, a meta-analysis was not performed due to limited scope and resources.

**Results:** Ten studies were included in the final review for the primary objective with 1,663 total study participants, and four for the secondary objective of detecting any stage of ROP. The sensitivity ranged from 80-100% and specificity from 35-100% for referral-warranted or treatment-requiring ROP. For any stage

ROP, the sensitivity and specificity ranged from 58.6-86% and 97.8-100%, respectively. Only two studies had a low risk of bias and the remaining studies had unclear or problematic methodological concerns.

**Conclusion:** The accuracy demonstrated by the included studies was not generalisable as they either had small sample sizes or were under the influence of bias, however the RetCam can be useful as an adjunct to BIO. Further research is required with larger cohorts in well controlled, prospective studies to establish the RetCam as a feasible substitute for BIO.

**Keywords:** retinopathy of prematurity, RetCam, diagnostic test accuracy, systematic review

## INTRODUCTION

Retinopathy of prematurity (ROP) is a vaso-proliferative disease of the immature retina that occurs in premature or low birth weight infants and is a leading cause of preventable childhood blindness.<sup>1</sup> The retinal vascular bed arising from the blood vessels in the optic nerve begins to develop at a gestational age (GA) of 20 weeks and it takes a further 20 to 22 weeks to develop completely to the temporal ora serrata, therefore infants born prematurely are at a higher risk of having avascular retinal areas.<sup>2</sup> Rates of survival of premature infants have increased in recent years due to improvements in neonatal care, particularly in middle to high income countries, which has led to a rise in the incidence of ROP.<sup>2,3</sup> This demonstrates the need for a more efficient and accessible alternative screening method for the sight-threatening disease. The gold standard diagnostic test for the screening of ROP is binocular indirect ophthalmoscopy (BIO) and there are declining numbers of trained ophthalmologists available for the number of infants requiring screening to conduct this bedside examination, particularly in remote areas.<sup>3</sup> The use of wide-field digital retinal imaging (WFDRI) devices for the initial screening of ROP may make screening more

Corresponding author: **Shannon Brown**  
Discipline of Orthoptics  
School of Allied Health, Human Services and Sport  
La Trobe University VIC 3086 Australia  
Email: ShannonBrown@lei.org.au  
Accepted for publication: 1st October 2021

accessible for more infants, leading to better outcomes for premature infants with ROP.<sup>4</sup> It also has the potential to reduce the burden on physicians to train and perform the screening whilst benefiting the clinics in reducing costs over time, with less physician resources utilised for bedside examinations.<sup>4</sup> A recent retrospective clinical audit supports this finding and suggests that ophthalmologist workload is reduced with introduction of nurse-led WRDRI.<sup>5</sup>

During screening, ROP is staged according to the International Classification of ROP (ICROP)2 based on three criteria:

- i. its location within three topographical zones of the retina, zone I being the central retinal area encompassing the optic disc and macula, zone II extending to the nasal ora serrata and zone III to the temporal ora serrata.<sup>2</sup>
- ii. the severity of the disease at the point of vascularisation in five stages from least to most advanced; 1 – demarcation line, 2 – ridge, 3 – extraretinal fibrovascular proliferation, 4 – partial retinal detachment, and 5 – total retinal detachment.<sup>2</sup>
- iii. the presence or absence of plus disease, where the posterior retinal vessels become tortuous and engorged.<sup>2,6</sup>

Early screening and treatment is essential to achieve good visual outcomes as demonstrated by the Early Treatment for Retinopathy of Prematurity (ETROP) trial.<sup>1</sup> Approximately 10% of infants who are screened reach a stage that requires treatment with cryotherapy, laser photocoagulation or anti-VEGF injections in order to prevent a total retinal detachment and blindness. This is most commonly defined as type 1 ROP or treatment-requiring ROP (TR-ROP), where the disease is in the more advanced stages and/or encompasses the central retinal areas.<sup>1,4,7</sup> Most cases of ROP are mild, more peripheral in nature and will spontaneously resolve and regress over time, these cases are classified as type 2 ROP.<sup>1,4,7</sup>

### Reference standard

Binocular indirect ophthalmoscopy with scleral depression is the current gold standard for the screening of ROP, performed by a paediatric ophthalmologist specialised in the disease.<sup>1</sup> The initial screening examination is performed at the bedside in neonatal intensive care units (NICUs) and requires the use of mydriatic and anaesthetic eye drops, and a lid speculum.<sup>1,2,8</sup> The examiner assesses and stages both eyes, and records results using handwritten or electronic notes and drawings of the retinal appearance.

### Index test

Wide-field digital retinal imaging is an alternative approach for the screening and monitoring of ROP.<sup>4,9</sup> The rapidly growing use of telemedicine has allowed for high-resolution images to

be captured and saved by a trained non-physician for remote interpretation and diagnosis.<sup>1,4</sup> It is becoming a favourable and more accessible option in many clinics. It does involve significant upfront costs to purchase the camera, and for the initial and ongoing training of staff to capture the images.<sup>1,4,6</sup> The RetCam is a portable WFDRI device and the most widely used in NICUs.<sup>6</sup> A key feature of the RetCam is a contact probe that can capture up to 130° of the fundus, with video recording and fluorescein angiographic capabilities. The examination also requires the use of mydriatic and anaesthetic eye drops, and a lid speculum.<sup>6</sup>

### Primary objective

To assess the diagnostic test accuracy of the RetCam, a wide-field digital retinal imaging device, versus binocular indirect ophthalmoscopy in the detection of referral-warranted or treatment-requiring retinopathy of prematurity in infants eligible for screening.

### Secondary objective

To assess the diagnostic test accuracy of the RetCam in detecting any stage of ROP, where data is available.

## METHOD

### Eligibility criteria

#### Study type

Prospective or retrospective, and comparative or cohort studies where all participants were assessed with both the index test and reference standard were included. Due to ongoing improvements in imaging technology, only studies published between 2010 and 2021 were included to ensure the most recent and relevant data was analysed. The studies must have had the sensitivity and specificity of the index test included, or sufficient data to calculate it otherwise.

#### Participants

Infants born prematurely at 32 weeks GA or earlier, weighing 1500g or less at birth, or otherwise deemed at a higher risk for ROP by their clinician, as per the recommendation of the American Academy of Paediatrics (AAP) and the American Association for Paediatric Ophthalmology and Strabismus (AAPOS).<sup>4</sup> Screening should commence when infants reach at least 31 weeks post-menstrual age and are at least four weeks postnatal age.<sup>2,4</sup> Guidelines vary between regions and clinics, depending on factors unique to their circumstances and this was considered during the study selection process.

#### Index test

The RetCam (any model), where the test is performed by any trained physician, nurse or technician, and the images are interpreted by an ophthalmologist onsite or via telemedicine.

### Reference standard

Binocular indirect ophthalmoscopy performed by an ophthalmologist.

### Target condition

The diagnosis of TR-ROP, also known as type 1 ROP, defined as; zone I, any stage, with plus disease; zone I, stage 3, with or without plus disease; zone II, stage 2 or 3, with plus disease.<sup>4</sup> The diagnosis of referral-warranted ROP (RW-ROP) defined as any zone I, any stage 3 or worse, or the presence of plus disease will also be included in this review.

### Exclusion criteria

- Studies using any WFDR device other than the RetCam to limit the impact of heterogeneity (eg different examination methods or wider/narrower fundal field of view)
- Studies where BIO is not performed on every patient, or not used as the reference standard, to ensure a direct comparison is made between the gold standard results and the RetCam images
- Studies where an ophthalmologist does not perform the index text interpretation were excluded to reflect a realistic clinical setting.

### Additional search limits

Language: English

Publication Year: 2010 – 2021

### Information sources

The following databases were electronically searched using a variation of the search strategy outlined in Table 1, inclusive of articles published 20th May 2021 and prior: CINAHL, PubMed, Embase, SCOPUS (Elsevier) and CENTRAL.

References used in clinical practice guidelines, conference abstracts and papers, and electronic searches of the following sources were conducted: Google Scholar, Australian Orthoptic Journal, British and Irish Orthoptic Journal, and American Orthoptic Journal.

The titles of papers in the reference lists of studies that were obtained in full text were assessed for any further studies that may be relevant.

### Study selection

All filtered search results from databases and other sources were exported to Endnote X9 (Clarivate Analytics)<sup>10</sup> for reference management. Duplicate studies were filtered out, the title and abstract of all remaining studies were then screened by a single reviewer and labelled 'possibly relevant' or 'not relevant'. Those deemed 'not relevant' were excluded, and the full text of all 'possibly relevant' studies were sourced, read, and further classified as 'include' or 'exclude' using a study selection spreadsheet created in Microsoft Excel<sup>11</sup> to assist in making objective decisions based on the eligibility criteria.

Table 1. Search strategy

Problem/population		Index test		Reference standard		Outcome
<b>Subject heading:</b> 'Retinopathy of prematurity'				<b>Subject heading:</b> 'Ophthalmoscopy'		
<b>Keywords<sup>^</sup></b> Retinopathy ROP 'Plus disease' 'Retrolental fibroplasia' <b>AND</b> Prematur* Infant Baby Babies Newborn Neonat*	<b>AND</b>	<b>Keywords<sup>^</sup></b> 'Retinal imaging' 'Digital retinal imaging' WFDR 'Wide field' 'Wide angle' RetCam 'Retina* photograph*' Telemedicine Telehealth	<b>AND</b>	<b>Keywords<sup>^</sup></b> 'Binocular indirect ophthalmoscop*' BIO 'Indirect Ophthalmoscop*'	<b>AND</b>	<b>Keywords<sup>^</sup></b> Detect* Screen* Diagnos* Grade Test Efficacy Accuracy

<sup>^</sup>All keywords in each column combined with OR

**Data extraction**

A pre-determined data extraction form was used to extract the following information from each included study at a minimum:

- Study title and author(s)
- Year of publication
- Location and clinical setting of data collection
- Study design (ie retrospective or prospective)
- Inclusion and exclusion criteria
- Screening guidelines for the study/clinic/region
- Participant characteristics (sample size, mean gestational age, mean birth weight, gender, ethnicity, comorbidities)
- Index test and reference standard descriptions
- Person/s executing and interpreting the index test and reference standard
- Any reported adverse events during testing
- Sensitivity and specificity of the index test with 95% CIs, where available
- Funding sources/conflicts of interest, if acknowledged.

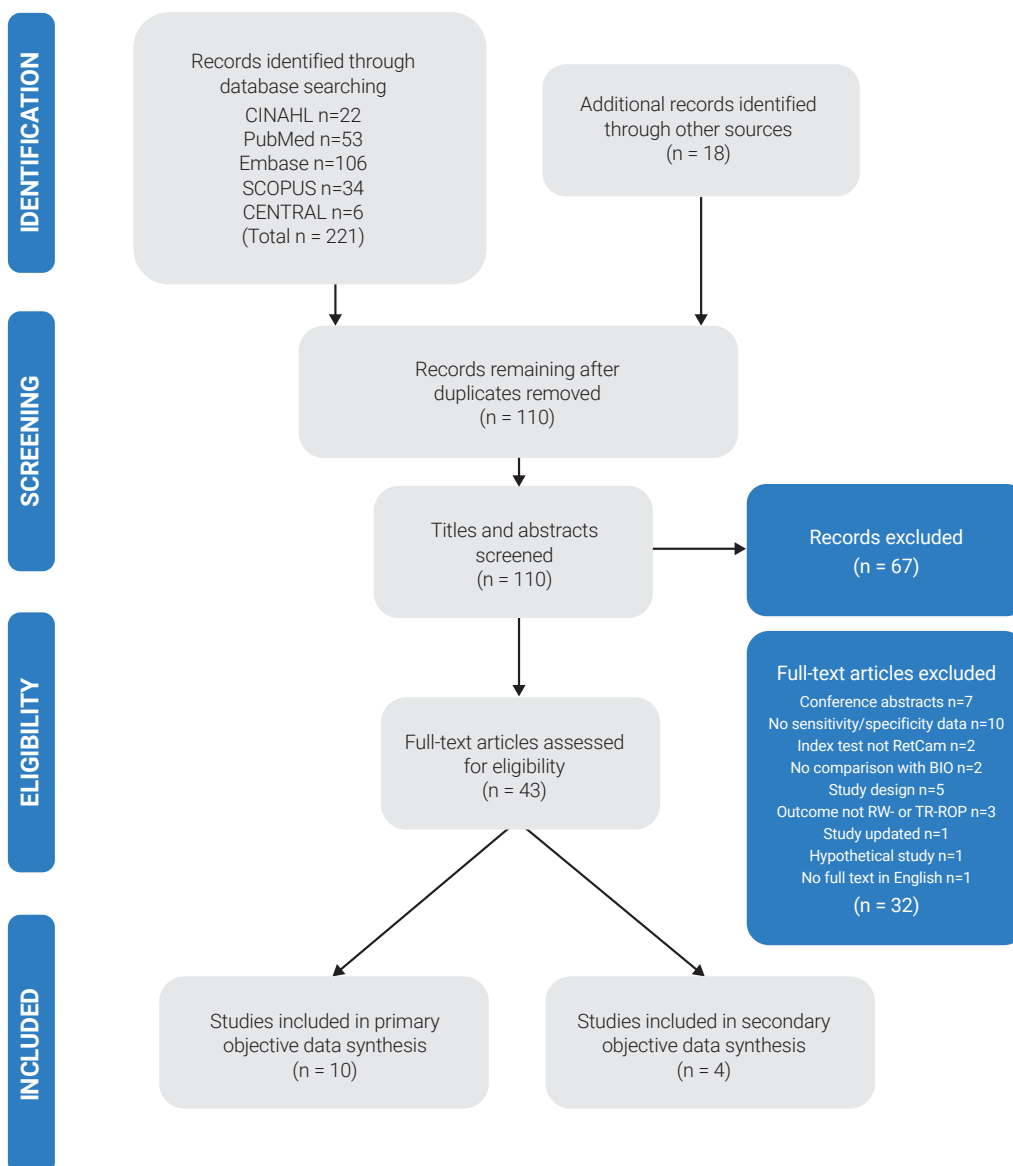
**Quality assessment**

The QUADAS-2 checklist was utilised on the selected studies to critically appraise their methodological soundness and the reliability of the results.<sup>12</sup> A tabular summary of the bias assessment was created using the QUADAS-2 template.<sup>12</sup> An overall assessment of low, high, or unclear risk was made for each study based on this checklist.

**Data analysis and synthesis**

Relevant data extracted from each study was presented in a study characteristics table to summarise the methodology. The quantitative data of sensitivity and specificity, with the authors' conclusions, and overall quality was presented in a summary of findings table.

A coupled forest plot of specificity and sensitivity with 95% confidence intervals was planned using the data from each study for presentation of the results in a graphical form,



**Figure 1.** PRISMA study selection flow diagram.

Adapted from: Moher D, Liberati A, Tetzlaff J, Altman DG, PRISMA Group. Preferred reporting items for systematic reviews and meta-analyses: the PRISMA statement. PLoS Med 2009;6(7): e1000097.

however this was not performed due to the absence of 95% CIs reported in most studies, limited scope and resources, and the heterogeneity between studies.

## RESULTS

### Search results

The databases, other sources, and citation searches yielded 239 results (see Figure 1 for an outline of the study selection process). After the removal of duplicates and the screening of titles and abstracts of remaining studies, 43 were deemed 'possibly relevant'. After a thorough assessment of the full text of these studies, 10 were included in the final review for analysis of the primary objective with a total of 1,663 study participants. Four were included for the secondary objective, with an overlap of three studies between them. The reasons for the exclusion of 32 studies are presented in Figure 1.

### Study characteristics

Table 2 presents a summary of the study characteristics. Publication dates ranged from 2010 to 2020 and spanned nine countries including four in North America, three in Europe, two in Oceania and two in Asia. Six of the included studies were prospective and four were retrospective. Eight of the 10 studies were based in NICUs, and the remaining two were located at specialised ROP wards or centres. All studies utilised the more recent RetCam models being the RetCam II, III, or Shuttle, and the imaging was conducted by both physicians and non-physicians (predominantly nurses). Seven studies described and utilised telemedicine systems for interpretation of the WFDR images, one was interpreted onsite, and two did not describe where the images were interpreted. Eight studies measured the outcome of type 1 ROP, and two measured RW-ROP, however there were some discrepancies as to how these were defined.

Study author	Year	Setting & country	Study design	Screening guidelines	Index test	Person(s) interpreting index test	Reference standard and testing order	ROP stage
Williams et al <sup>13*</sup>	2010	1 NICU, USA	Prospective	GA ≤32 weeks, BW ≤1500g, or otherwise high risk	3-5 images per eye on RetCam II by neonatal nurse	Remotely by 3 ROP ophthalmologists	BIO before index test by 1 of 2 paediatric ophthalmologists	TR-ROP (type 1 ROP)
Dai et al <sup>14</sup>	2011	1 NICU, NZ	Retrospective	GA ≤30 weeks, BW ≤1250g, or otherwise high risk	3+ images per eye on RetCam II by paediatric ophthalmologist A	Remotely by paediatric ophthalmologist B	BIO after index test by paediatric ophthalmologist A	TR-ROP (type 1 ROP)
Weaver & Murdock <sup>15</sup>	2012	1 NICU, USA	Retrospective	GA ≤32 weeks, BW ≤1500g, or otherwise high risk	5 images per eye on RetCam II by NICU nurse	Remotely by 1 of 2 paediatric ophthalmologists	BIO after index test by ophthalmologist	type 1 ROP
Sekeroglu et al <sup>16</sup>	2013	1 ROP Centre, Turkey	Prospective	GA ≤32 weeks, BW ≤1500g, or otherwise high risk	3 images per eye on RetCam Shuttle by paediatric ophthalmologist A	Onsite by paediatric ophthalmologist A	BIO before index test by ophthalmologist B	TR-ROP (type 1 ROP)
Quinn et al <sup>17*</sup>	2014	13 NICUs, USA & Canada	Prospective	BW <1251g, screening began at 32 weeks PMA	5 images per eye on RetCam Shuttle by 25 non-physicians	Remotely by 3 ROP ophthalmologists	BIO in alternating order to index test by a different ophthalmologist	RW-ROP
Wang et al <sup>18</sup>	2015	6 NICUs, USA	Retrospective	GA ≤32 weeks, BW ≤1500g, or otherwise high risk	5 images per eye on RetCam II or III by NICU nurses	Remotely by ROP specialist	BIO after index test by paediatric retinal ophthalmologist	TR-ROP (type 1 ROP)
Wongwai et al <sup>19</sup>	2018	5 NICUs, Thailand	Prospective	Varied with hospital	4 images per eye on RetCam Shuttle by trained technician	2 ROP specialists	BIO before index test by ROP ophthalmologist	TR-ROP (type 1 ROP)
Karkhaneh et al <sup>20</sup>	2019	Eye Hospital, Iran	Prospective	All patients referred to ROP ward (criteria not stated)	RetCam Shuttle by nurses	Remotely by 4 retinal specialists	BIO before index test by ophthalmologist	RW-ROP (type 1 ROP)
Maka et al <sup>21</sup>	2019	2 NICUs, Hungary	Retrospective	GA ≤32 weeks, BW ≤1500g, or otherwise high risk	RetCam Shuttle by paediatric ophthalmologist A or neonatal nurse practitioner	ROP ophthalmologist B	BIO after index test by paediatric ophthalmologist A	TR-ROP (type 1 ROP)
Athikarisamy et al <sup>22</sup>	2020	1 NICU, Australia	Prospective	GA ≤31 weeks, BW ≤1250g	5 images per eye on RetCam by neonatal nurses	Remotely by ophthalmologist A	BIO in alternating order to index test by ophthalmologist B	RW-ROP

**NICU** Neonatal Intensive Care Unit, **GA** gestational age, **BW** birth weight, **PMA** postmenstrual age, **BIO** binocular indirect ophthalmoscopy, **TR-ROP** treatment-requiring retinopathy of prematurity, **RW-ROP** referral-warranted retinopathy of prematurity

\*Study examined accuracy of both expert (physician) and non-physician graders. Only the method and results of expert graders were included in this review.

**Study findings**

Table 3 outlines the findings for each study included in the analysis of the primary objective, and Table 4 for the secondary objective. For analysis of the primary objective of TR-ROP or RW-ROP, the sensitivity across the 10 studies ranged from 80%

to 100% and the specificity ranged from 35% to 100%, eight of which had a specificity of greater than 90%. For the analysis of the secondary objective, across four studies the sensitivity ranged from 58.6% to 86% and specificity 97.8% to 100%.

**Table 3. Primary objective summary of findings: treatment-requiring or referral-warranted ROP**

Study author	Sample size	Sensitivity (%) [95% CI]	Specificity (%) [95% CI]	Study conclusions	Quality comment
Williams et al <sup>13*</sup>	67 infants	100	93.0	Telemedicine systems for ROP must have rigorous protocols for imaging quality and timing	Unclear risk 'Unknown' diagnoses excluded.
Dai et al <sup>14</sup>	108 infants	100 [76.2-100]	97.9 [93.4-99.7]	Index test is an accurate, reliable, and cost-efficient method for ROP screening, but more training and imaging protocols required for wide use of WFDR1	High risk Ophthalmologist performing BIO not masked to index test images.
Weaver & Murdock <sup>15</sup>	137 infants	100	96.3	Telemedicine screening of ROP using index test useful in this specific remote NICU, more studies required for generalisability	High risk BIO not simultaneous with index test, and ophthalmologist performing BIO not masked to patients ROP status from index test.
Sekeroglu et al <sup>16</sup>	58 infants	100	100	Index test was accurate in detecting ROP needing treatment but should only be used as an adjunct to BIO	Low risk
Quinn et al <sup>17*</sup>	200 infants	85.9 [80.8-89.8]	56.6 [51.9-61.0]	Expert interpretation of RetCam had poorer accuracy compared to non-physician graders	High risk Case-control sample of infants
Wang et al <sup>18</sup>	608 infants	100	99.8	Telemedicine screening using index test a safe, accurate and cost-effective complement to BIO to increase access and address future needs	High risk BIO not simultaneous with index test, and ophthalmologist performing BIO not masked to patients ROP status from index test
Wongwai et al <sup>19</sup>	100 infants	100	96.7	Index test has good diagnostic accuracy for ROP screening	Unclear risk Variable screening guidelines used for patient inclusion criteria
Karkhaneh et al <sup>20</sup>	147 infants	85.0	35.0	Index test cannot be used as a substitute for BIO, but it can be useful	Unclear risk Inadequate description of patient inclusion criteria/screening guidelines
Maka et al <sup>21</sup>	153 infants	100 [87-100]	100 [99-100]	Index test is a useful and efficient method for ROP screening but cannot replace BIO	High risk Ophthalmologist performing BIO not masked to index test images for some patients
Athikarisamy et al <sup>22</sup>	85 infants	80.0 [28.4-99.5]	94.5 [90.2-97.3]	Index test was an acceptable and effective method for ROP screening in this particular setting.	Low risk

\*Study examined accuracy of both expert (physician) and non-physician graders. Only the method and results of expert graders were included in this review.

### Study quality

Table 5 presents a quality summary of each study. Using the QUADAS-2<sup>12</sup> checklist, two studies had an overall low risk of bias with no applicability concerns. Three had an unclear risk of bias due to a lack of clarity around screening guidelines, or unexplained exclusions. The remaining five studies were deemed to be of a higher risk of bias, four of these due to flow and timing issues that introduced bias for the performance of the reference standard, and the fifth study due to a case-control sample of infants utilised in the expert analysis of the index test. All studies except one had relatively small sample sizes. The nature of the four retrospective studies included in the review places them at a higher risk of bias for the patient selection and data analysis. One study, Williams et al<sup>13</sup> received grants from an unpaid member of the scientific board for Clarity Medical Systems, the manufacturer of the RetCam, no other studies had any declared conflicts of interest.

## DISCUSSION

### Primary objective

As outlined in Table 3, the studies included in this review had an overall high sensitivity and specificity, however their combination of quality, sample size, and reported accuracy are not sufficiently consistent to present a conclusive outcome with regards to the detection of RW-ROP or TR-ROP using the RetCam.

The high reported sensitivity among the included studies indicates that a significant proportion of infants confirmed as positive for RW-ROP or TR-ROP with BIO were also detected with the RetCam. Eight of the ten studies correctly diagnosed all infants with RW-ROP or TW-ROP that were identified via the gold standard. The specificity across these studies indicates that there were low numbers of unnecessary referrals or false positive tests in most instances. Sekeroglu et al<sup>16</sup> and Athikarisamy et al<sup>22</sup> were the only two papers with a low risk of bias included in this review. The former had 100% accuracy for both sensitivity and specificity but had the smallest sample size of all studies with 58 infants. The latter reported the lowest sensitivity of 80%, and a specificity of 94.5%, but also had a small sample size of 85 infants, which raises concerns about the generalisability of the results from both studies.

Quinn et al<sup>17</sup> had a high risk of bias due to the case-control sample of 100 disease-positive and 100 disease-negative infants utilised in the expert interpretation of the index test. This is likely to cause an overestimation of the reported sensitivity and specificity of 85.9% and 56.6%, respectively.

Dai et al,<sup>14</sup> Weaver and Murdock,<sup>15</sup> and Maka et al<sup>21</sup> demonstrated evidence of a risk of information bias for the reference standard, the ophthalmologists performing BIO were not masked to either the RetCam images or their interpretation for methodological reasons. All three studies had small sample sizes and reported

**Table 4. Secondary objective summary of findings – any stage ROP**

Study author and year	Study characteristics	Sensitivity (%) [95% CI]	Specificity (%) [95% CI]	Quality comment
Sekeroglu et al <sup>16</sup> (2013)	Prospective study of 58 infants of GA ≤32 weeks, BW ≤1500g in a ROP centre in Turkey. RetCam shuttle performed & interpreted by an ophthalmologist. BIO performed prior by a second ophthalmologist.	58.6	100	Low risk
Tejada-Palacios et al <sup>23</sup> (2015)	Prospective study of 83 Infants of GA ≤30 weeks, BW ≤1250g in a Neonatology Unit in Spain. RetCam II performed and interpreted by unknown. BIO performed by ophthalmologist as reference standard. Outcome measure of any stage ROP.	68 [59-76]	99 [97-100]	Unclear risk Unclear methodology
Wongwai et al <sup>19</sup> (2018)	Prospective study based out of five NICUs in Thailand including 100 infants. RetCam shuttle performed by technician and interpreted by two ROP specialists. BIO performed prior by a ROP ophthalmologist.	40.3	97.8	Unclear risk Variable screening guidelines used for patient inclusion criteria
Maka et al <sup>21</sup> (2019)	Retrospective study of 153 infants of GA ≤32 weeks, BW ≤1500g at two NICUs in Hungary. RetCam images captured by an ophthalmologist or nurse practitioner and interpreted by a second ophthalmologist. BIO performed by same ophthalmologist as the RetCam after images captured.	86	98.5	High risk Ophthalmologist performing BIO not masked to index test images for some patients

high sensitivity of 100% and specificity between 96.3% and 100%, but the high risk of bias is likely to overestimate these results. Wang et al<sup>18</sup> was the only study with both a large sample size of 608 infants and a reported high accuracy for the RetCam. However, this study is also subject to a high risk of information bias for the reference standard as determined by the QUADAS-2 checklist, therefore its results are also likely overestimated.

The three key factors in determining the power of the body of research for each study are the methodological impact on quality and risk of bias, the sample size, and the reported accuracy for the index test. Considering these factors, none of the studies included in this review adequately demonstrated all three for the diagnosis of RW-ROP or TR-ROP, however the overall conclusions made by the 10 studies agreed that the RetCam is sufficiently accurate in identifying treatment-requiring ROP when used in clinical practice in addition to BIO.

**Secondary objective**

Due to the peripheral nature of ROP in its less severe stages, and the limitation of the RetCam in capturing more than 130° of the fundus, the range of sensitivity of the RetCam in detecting any stage of ROP reported from 58.6% to 86% by the four studies is not unexpected. These figures demonstrated that many cases of mild ROP were missed using the RetCam, however the clinical impact of this is not as significant as TR-ROP or RW-ROP, due to the spontaneous recovery seen in these milder cases. The specificity ranged from 97.8% to 100%, indicating low false positive results, however, due to the risk of bias and inadequate sample size in this small number of studies, it is difficult to be certain if these reported results are reliable.

**Strengths and limitations of the review**

This review was limited by the inclusion of papers only in English, and more significantly limited by the availability of only a single reviewer to perform the study selection and quality assessment process. While due care was taken to ensure relevant studies were not missed, there is no absolute certainty that all pertinent data has been included. The bias and small sample sizes present across most studies was another limitation for this review. While the inclusion criteria of only ophthalmologists interpreting the index test images allowed for a more controlled review with real-world applicability, the inclusion of non-physician trained retinal readers may have allowed for a larger sample size of infants to be included from more studies, and possibly of better quality. Additionally, expanding the eligibility criteria to include other WFDR models available on the market, including non-contact cameras, may also have allowed for higher-quality studies to be found, despite contributing to heterogeneity.

All studies were a direct comparison between the index test and reference standard, and the study selection process endeavoured to be as objective as possible. A rigorous search strategy was implemented across five databases, including thorough citation searching, this is a well-structured approach and is a strong point for this review.

**Implications for practice**

The current and most widely used screening guidelines for ROP published by the AAP and AAPOS recommend that a dilated BIO examination is to be performed by an ophthalmologist with experience in ROP to obtain stereoscopic, wide-field views of the

**Table 5. QUADAS-2 Quality assessment summary<sup>12</sup>**

Study	Risk of bias				Applicability concerns		
	Patient selection	Index test	Reference standard	Flow and timing	Patient selection	Index test	Reference standard
Williams et al <sup>13</sup>	😊	😊	😊	?	😊	😊	😊
Dai et al <sup>14</sup>	?	😊	😞	😊	😊	😊	😊
Weaver & Murdock <sup>15</sup>	?	😊	😞	😞	😊	😊	?
Sekeroglu et al <sup>16</sup>	😊	😊	😊	😊	😊	😊	😊
Quinn et al <sup>17</sup>	😞	?	😊	?	😞	😊	😊
Tejada-Palacios et al <sup>23</sup>	😊	?	😊	?	😊	?	😊
Wang et al <sup>18</sup>	?	😊	😞	😞	😊	😊	?
Wongwai et al <sup>19</sup>	?	😊	😊	😊	?	😊	😊
Karkhaneh et al <sup>20</sup>	?	😊	😊	😊	?	😊	😊
Maka et al <sup>21</sup>	?	😊	😞	😊	😊	😊	😊
Athikarisamy et al <sup>22</sup>	😊	😊	😊	😊	😊	😊	😊

😊 Low Risk    😞 High Risk    ? Unclear Risk



fundus.<sup>6</sup> In the most recent update to the guidelines published in 2018, there is mention of the increasing use of WFDRI in ROP screening and the published literature up to that point.<sup>6</sup> They also highlighted the importance of developing strict protocols for training and imaging capture to ensure high quality images are available for interpretation, and to follow the same timing recommendations as for BIO.<sup>6</sup> They also recommended that all patients should continue to be examined by BIO at least once before any treatment commences or screening is ceased.<sup>6</sup>

If the RetCam was recognised as an appropriate alternative for the screening and monitoring of ROP, clearer guidelines would need to be developed to ensure standardisation of training for the photographers and interpretation. As described by Dai et al,<sup>14</sup> Weaver and Murdock,<sup>15</sup> and Maka et al,<sup>21</sup> if WFDRI was successfully established using a telemedicine system, the costs associated with infant transport, and physician time would be greatly reduced. Additionally, accessibility to ROP care would improve and it would address the workforce challenges faced in the ophthalmology speciality.

The conclusions made by the authors of the included studies in this review were varied, Sekeroglu et al<sup>16</sup> and Maka et al<sup>21</sup> both reported 100% sensitivity and specificity but concluded that the RetCam should not be used as a replacement for BIO, only as an adjunct. Some studies with good accuracy recommended that further research for more generalisable results and the development of better protocols is required. Others reporting lower accuracy concluded that it was a suitable alternative for screening in their setting.

Whilst this review agrees that there is insufficient high-quality evidence to recommend the use of the RetCam across all settings as a replacement for BIO, the RetCam remains a highly useful and effective imaging device for ROP until further research is conducted and reviewed. WFDRI creates an objective record of the infants' fundus to be saved indefinitely for future reference, or for teaching purposes. As demonstrated by Weaver and Murdock,<sup>15</sup> the RetCam can be used as the primary screening or triaging tool in very remote clinics with scarce resources. They also performed a cost analysis for the transfer of all infants for BIO, versus only transferring those detected with type 1 ROP and found the overall costs were greatly reduced when using the RetCam in the first instance onsite, despite the upfront cost of purchasing the camera.<sup>15</sup> An earlier study performed by Dhaliwal et al<sup>24</sup> recommended that WFDRI can be used as an initial and ongoing screening tool, however all infants should undergo BIO before discharge from the NICU to ensure full vascularisation to the peripheral retina. This recommendation is supported by the secondary findings of this review for any stage ROP, where signs of ROP in the peripheral zones were missed with the RetCam due to its limited field of view.

## CONCLUSION

This review has confirmed that further research needs to be conducted before WFDRI can be clinically accepted as an alternative to binocular indirect ophthalmoscopy. Prospective, longitudinal studies are required with larger sample sizes, index test and reference standard performed consecutively, blind interpretation, and clear patient sampling methods. Based on the results of this review, wide-field digital retinal imaging using the RetCam can be useful as an adjunct or as an initial screening tool for triaging purposes, but the current evidence has not demonstrated that it is an accurate alternative to the gold standard.

## REFERENCES

1. Salcone EM, Johnston S, VanderVeen D. Review of the use of digital imaging in retinopathy of prematurity screening. *Semin Ophthalmol* 2010;25(5-6):214-217.
2. Reynolds JD. Retinopathy of prematurity. In: Nelson LB, Olitsky SE, editors. *Harley's Pediatric Ophthalmology*. 6th Ed. Philadelphia: Lippincott Williams & Wilkins; 2013. p.72-92.
3. Sabri K. Global challenges in retinopathy of prematurity screening: modern solutions for modern times. *Pediatrics* 2016;137(1):e20152256.
4. Kychenthal AB, Dorta PS, editors. *Retinopathy of Prematurity: Current Diagnosis and Management*. Cham: Springer; 2017.
5. Tram JS, Golding BM, Lim C, et al. Changed ophthalmic workload following introduction of digital retinal photography for retinopathy of prematurity screening. *Clin Exp Ophthalmol* 2021;49(4):368-372.
6. Fierson WM, American Academy of Pediatrics Section on Ophthalmology, American Academy of Ophthalmology, et al. Screening examination of premature infants for retinopathy of prematurity. *Pediatrics* 2018;142(6):e20183061.
7. Jing C, Stahl A, Hellstrom A, Smith LE. Current update on retinopathy of prematurity: screening and treatment. *Curr Opin Pediatr* 2011;23(2):173-178.
8. Mitchell AJ, Green A, Jeffs DA, Robertson PK. Physiologic Effects of retinopathy of prematurity screening examinations. *Adv Neonatal Care* 2011;11(4):291-297.
9. Trese MT. Subjectivity in retinopathy of prematurity screening. *Am J Ophthalmol* 2015;160(3):406-407.
10. The Endnote Team. *EndNote X9* ed. Philadelphia: Clarivate Analytics; 2013.
11. Microsoft Corporation. *Microsoft Excel* 2018. Available from: <https://office.microsoft.com/excel>.
12. University of Bristol. QUADAS-2; 2011 [Cited 2020 10th Aug] Available from <https://www.bristol.ac.uk/population-health-sciences/projects/quadas/quadas-2/>.
13. Williams SL, Wang L, Kane SA, et al. Telemedical diagnosis of retinopathy of prematurity: accuracy of expert versus non-expert graders. *Br J Ophthalmol* 2010;94(3):351-356.
14. Dai S, Chow K, Vincent A. Efficacy of wide-field digital retinal imaging for retinopathy of prematurity screening. *Clin Exp Ophthalmol* 2011;39(1):23-29.
15. Weaver DT, Murdock TJ. Telemedicine detection of type 1 ROP in a distant neonatal intensive care unit. *J AAPOS* 2012;16(3):229-233.

16. Sekeroglu MA, Hekimoglu E, Sekeroglu HT, Arslan U. Alternative methods for the screening of retinopathy of prematurity: binocular indirect ophthalmoscopy vs wide-field digital retinal imaging. *Eye (Lond)* 2013;27(9):1053-1057.
17. Quinn GE, Ying GS, Daniel E, et al. Validity of a telemedicine system for the evaluation of acute-phase retinopathy of prematurity. *JAMA Ophthalmol* 2014;132(10):1178-1184.
18. Wang SK, Callaway NF, Wallenstein MB, et al. SUNDROP: six years of screening for retinopathy of prematurity with telemedicine. *Can J Ophthalmol* 2015;50(2):101-106.
19. Wongwai P, Suwannaraj S, Asawaphureekorn S. Diagnostic accuracy of a digital fundus photographic system for detection of retinopathy of prematurity requiring treatment (ROP-RT). *PLoS One* 2018;13(7):e0201544.
20. Karkhaneh R, Ahmadrabi A, Esfahani MR, et al. The accuracy of digital imaging in diagnosis of retinopathy of prematurity in Iran: a pilot study. *J Ophthalmic Vis Res* 2019;14(1):38-41.
21. Maka E, Kovács G, Imre L, et al. The validity of telemedicine-based screening for retinopathy of prematurity in the Premature Eye Rescue Program in Hungary. *J Telemed Telecare* 2021;27(6):367-375.
22. Athikarisamy SE, Lam GC, Ross S, et al. Comparison of wide field imaging by nurses with indirect ophthalmoscopy by ophthalmologists for retinopathy of prematurity: a diagnostic accuracy study. *BMJ Open* 2020;10(8):e036483.
23. Tejada-Palacios P, Zarratea L, Moral M, de la Cruz-Bértolo J. Comparative study of RetCamRetCam II vs. binocular ophthalmoscopy in a screening program for retinopathy of prematurity. *Arch Soc Esp Oftalmol* 2015;90(8):373-378.
24. Dhaliwal C, Wright E, Graham C, et al. Wide-field digital retinal imaging versus binocular indirect ophthalmoscopy for retinopathy of prematurity screening: a two-observer prospective, randomised comparison. *Br J Ophthalmol* 2009;93(3):355-359.